

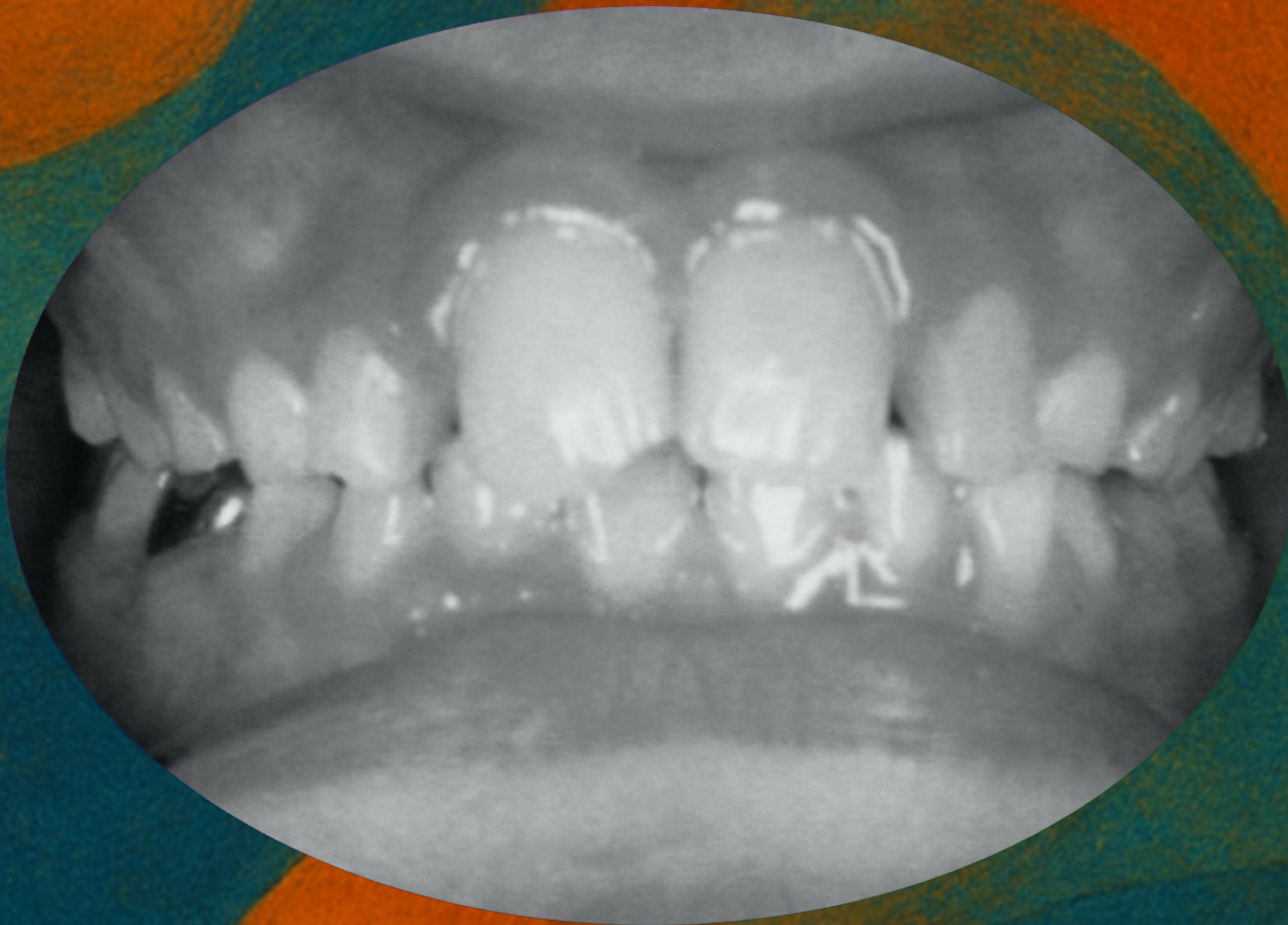www.odontologiasistemica.com

Clinical Case



Clinical Case:

- Lack of space for the eruption of some teeth
- Respiratory problems such as rhinitis and asthma
- Poor body posture

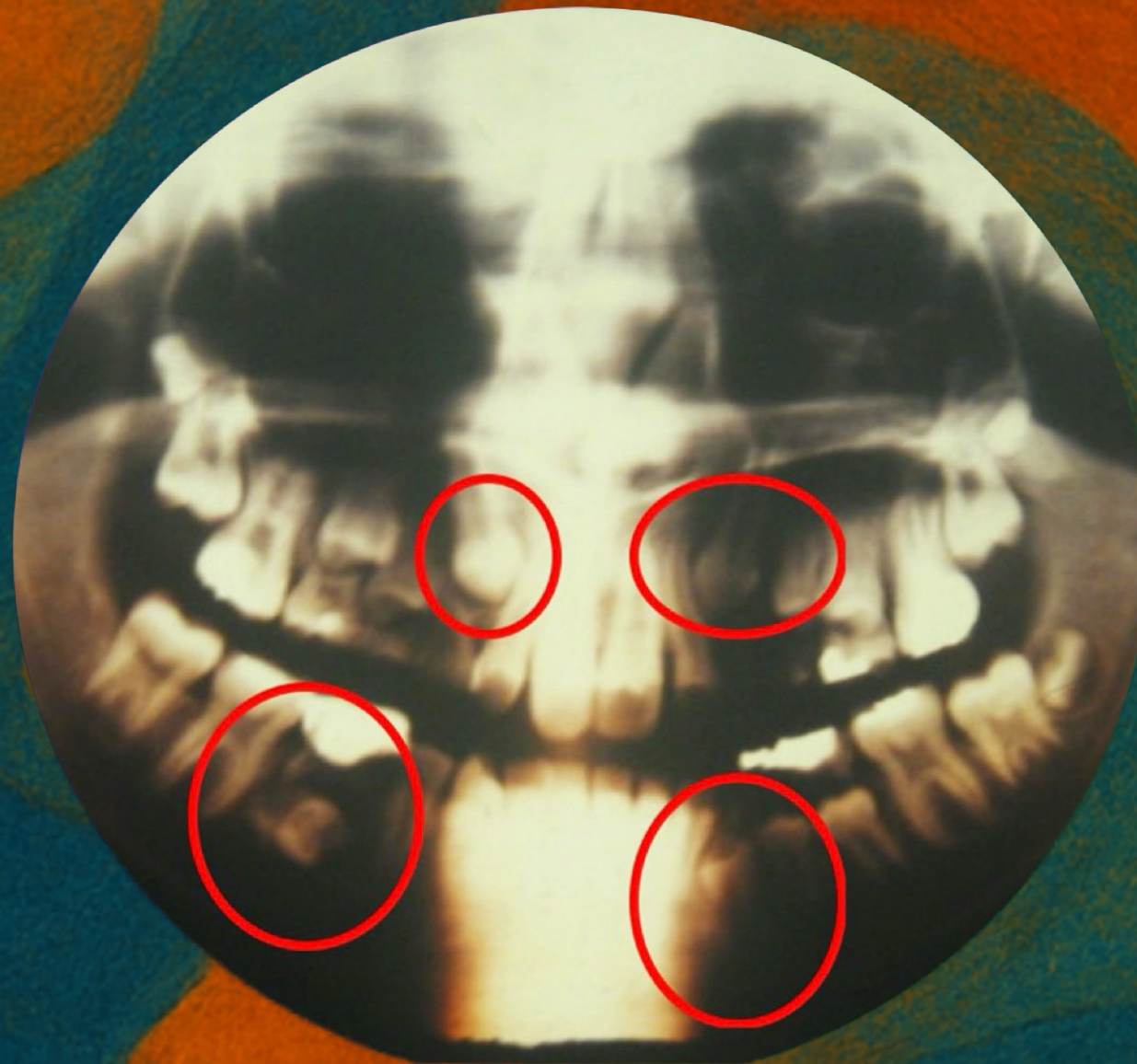


Patient D I – 10 years old



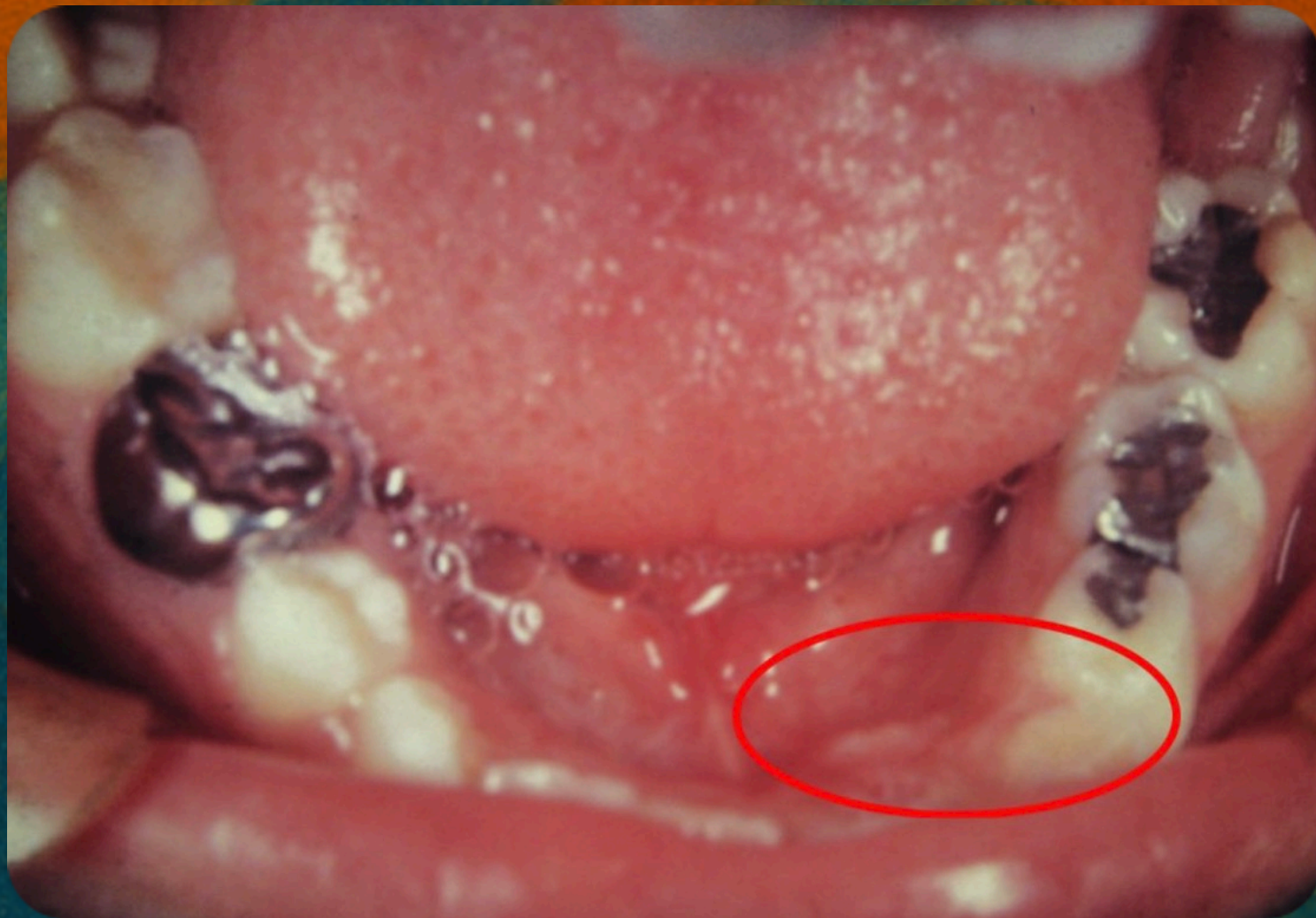Teeth 13, 23, 33, and 45 were intraosseous and in unfavorable positions for eruption.

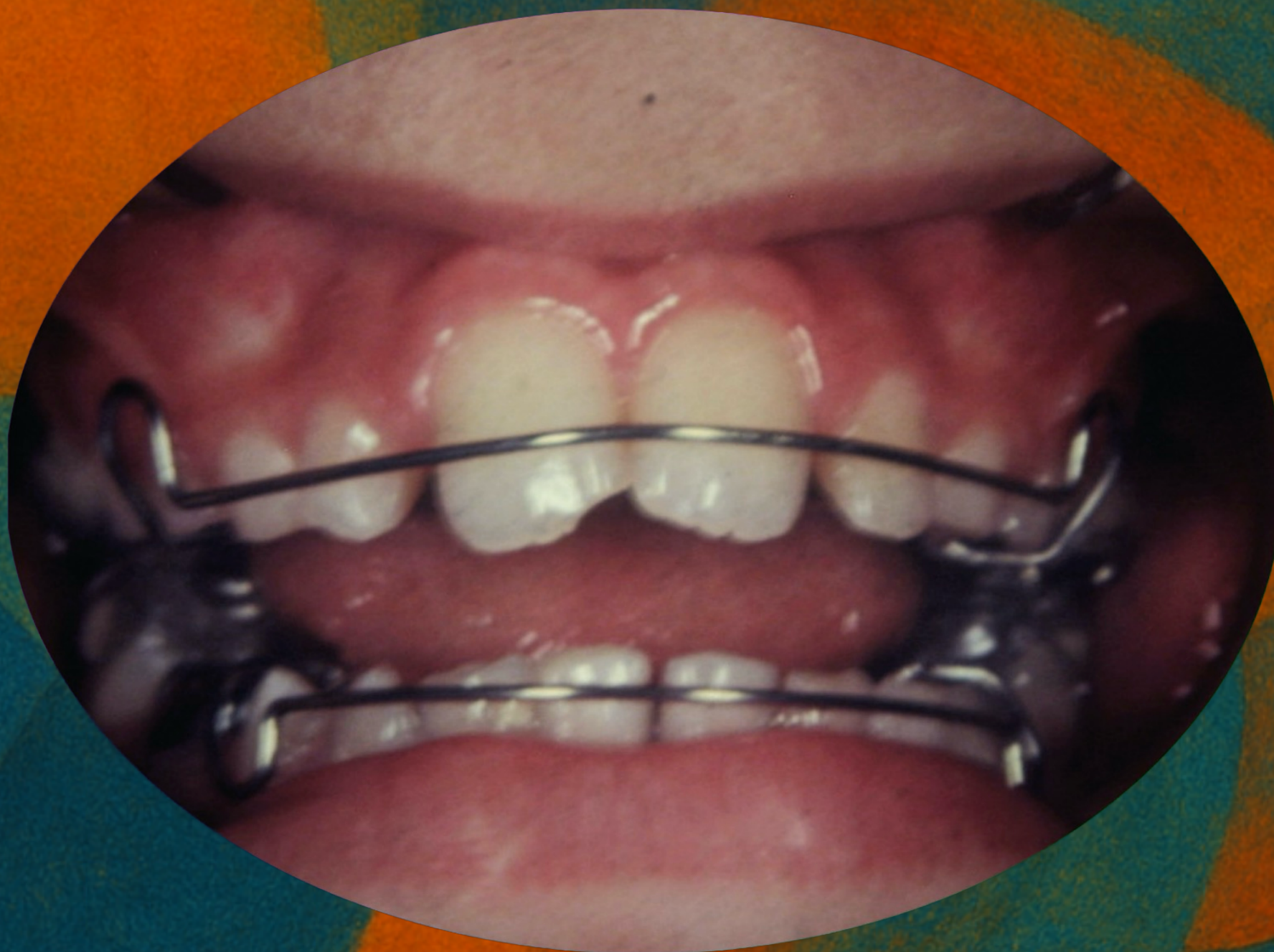RDFM distalization appliances were used to reposition these teeth.

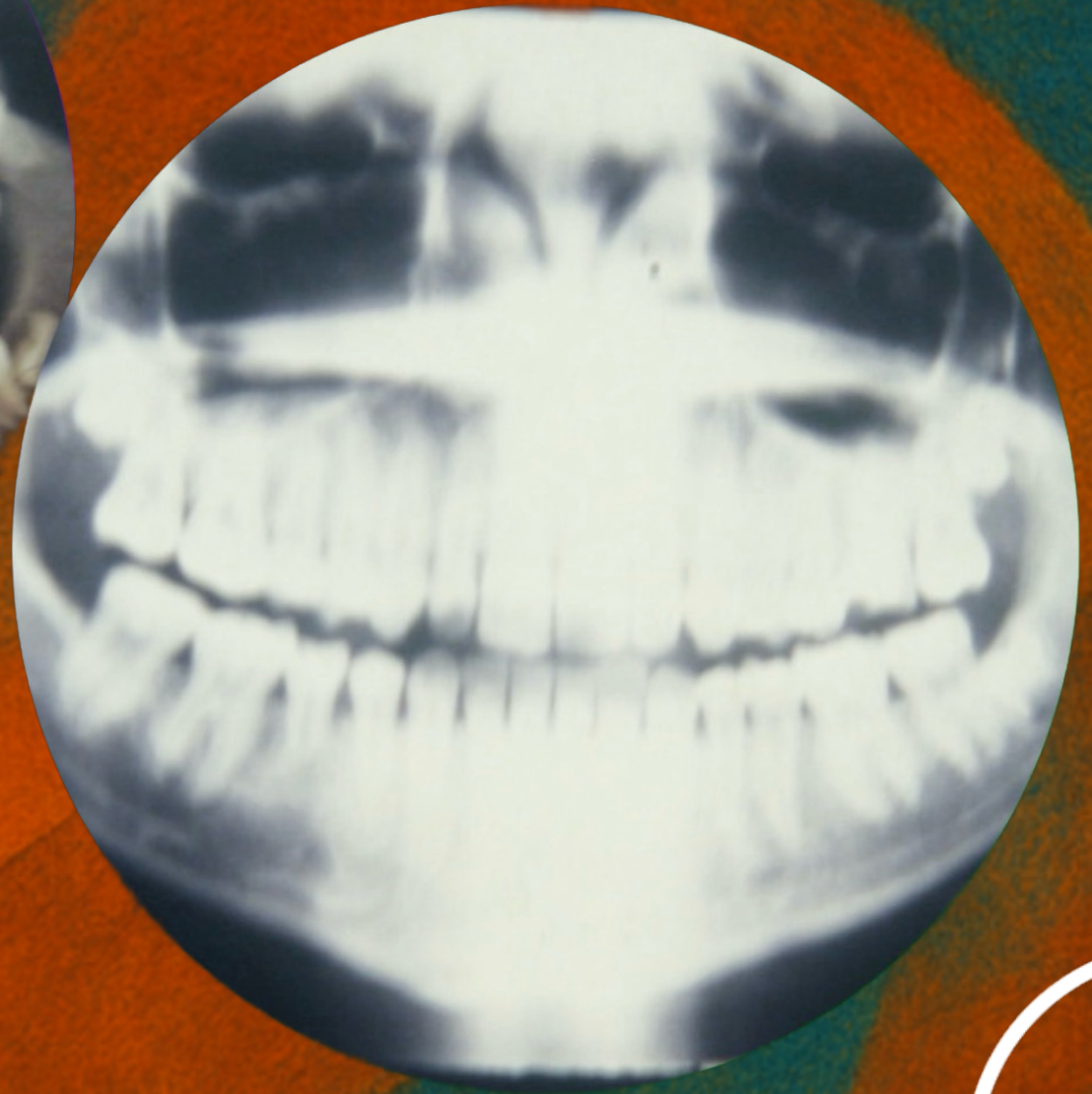
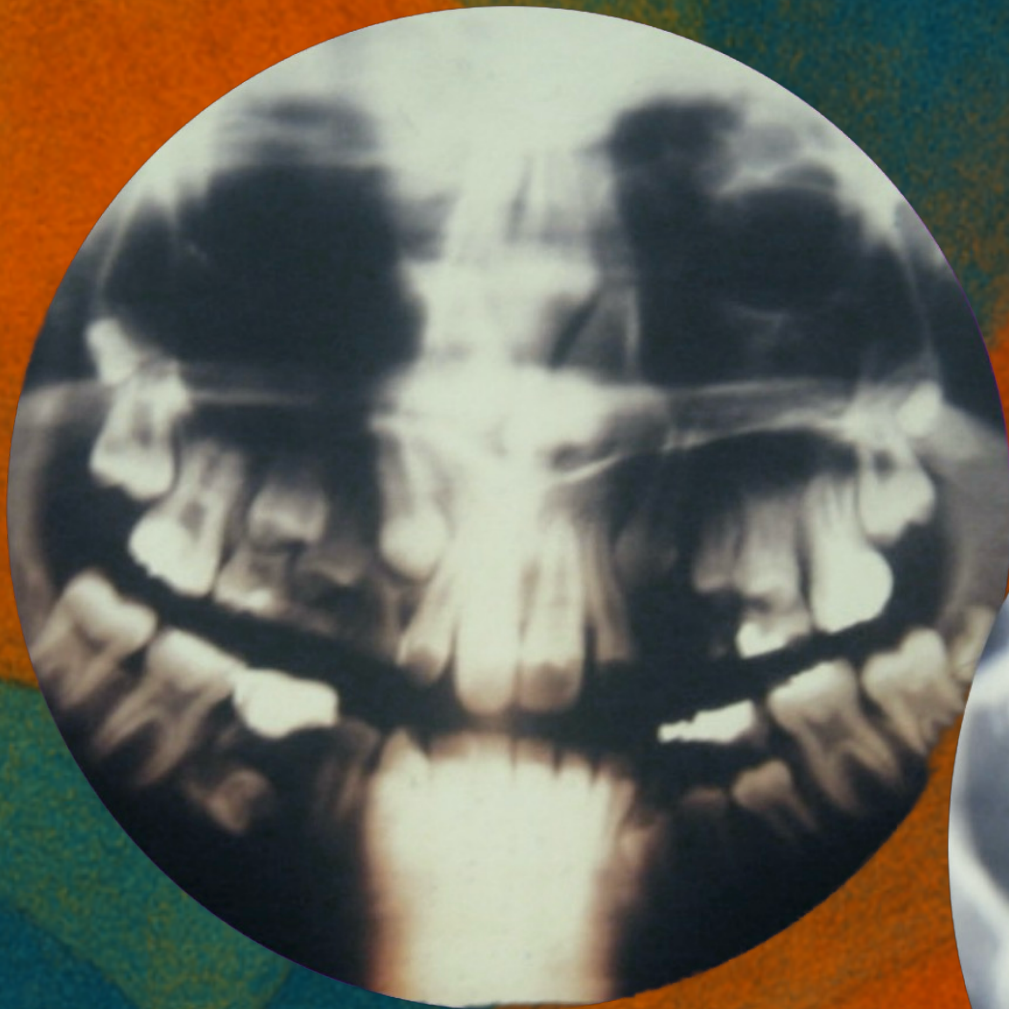
Retention of the deciduous tooth in the arch and lingual inclination of tooth 32, with no space available for the eruption of tooth 33.

RDFM distalization and bilateral expansion appliances were used.

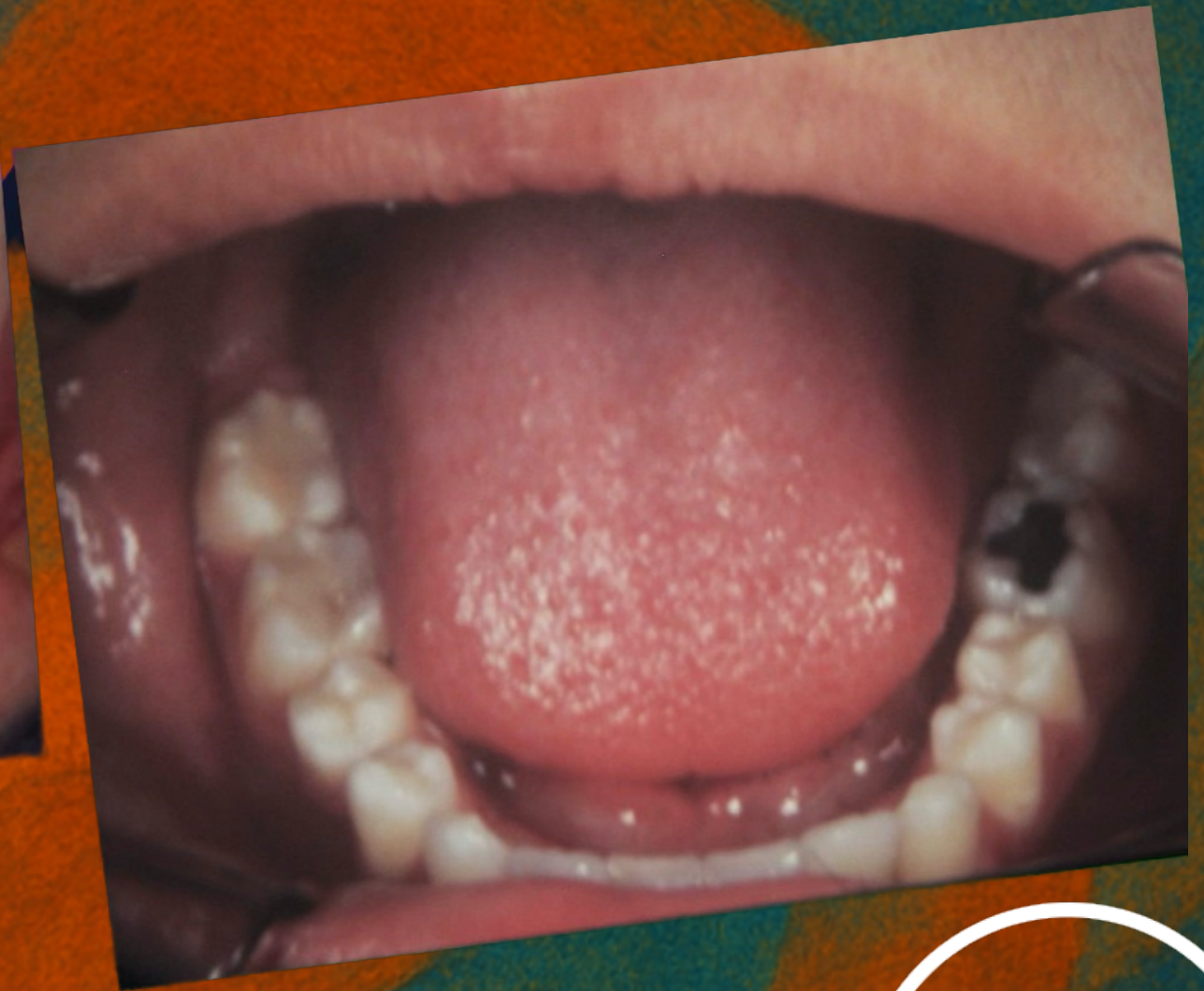
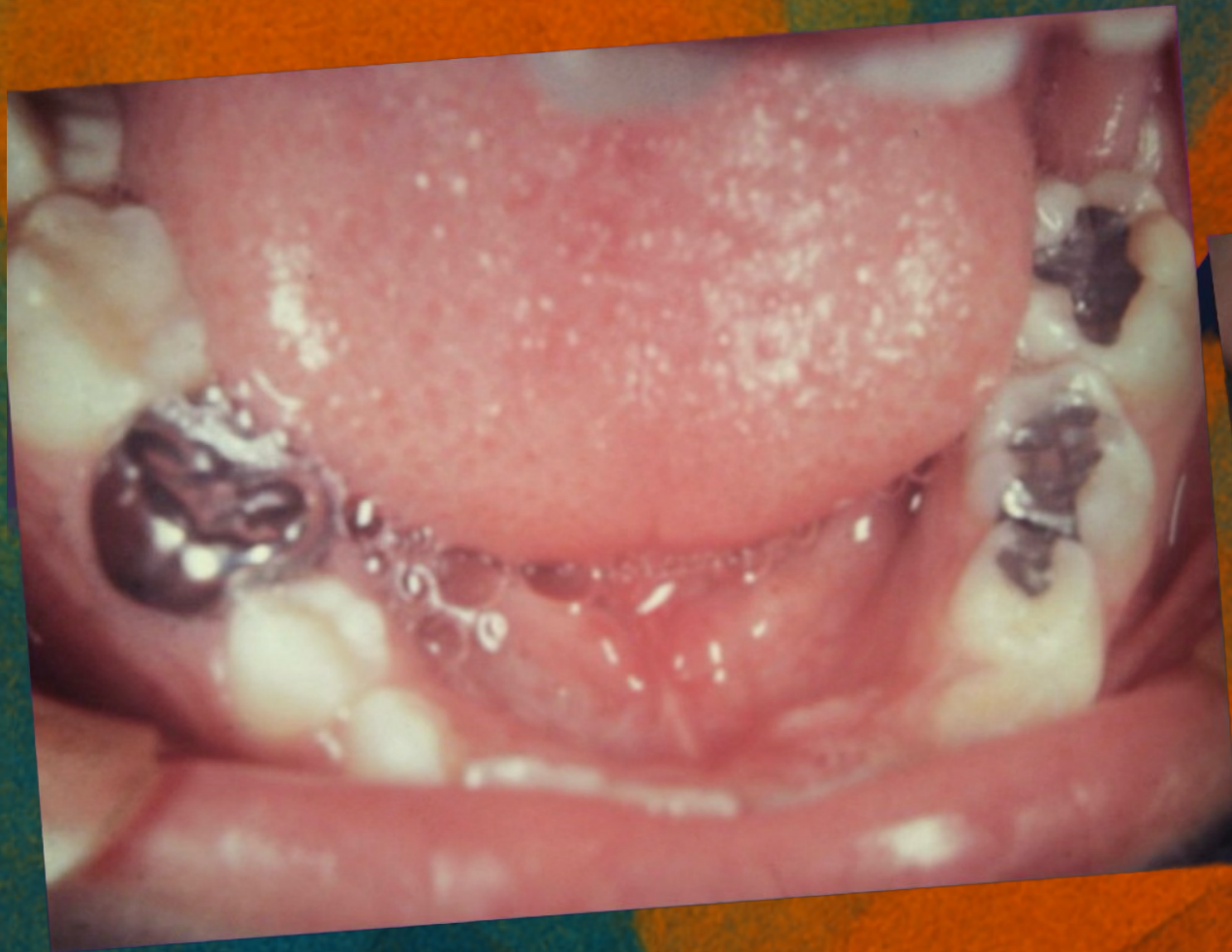




Before and After

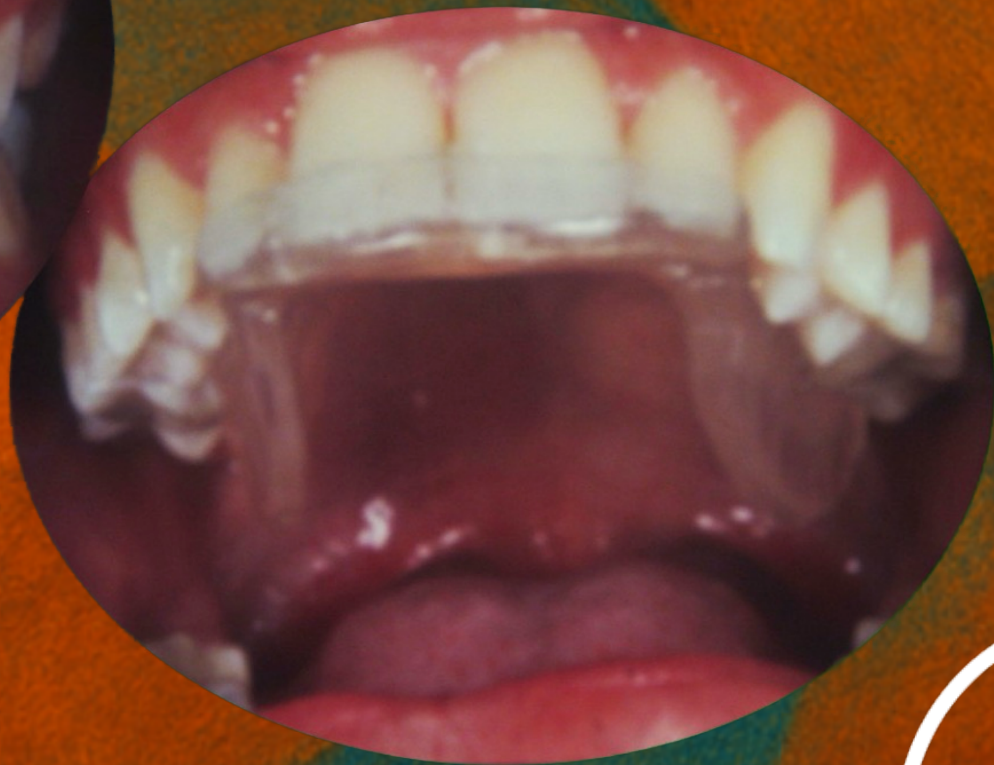
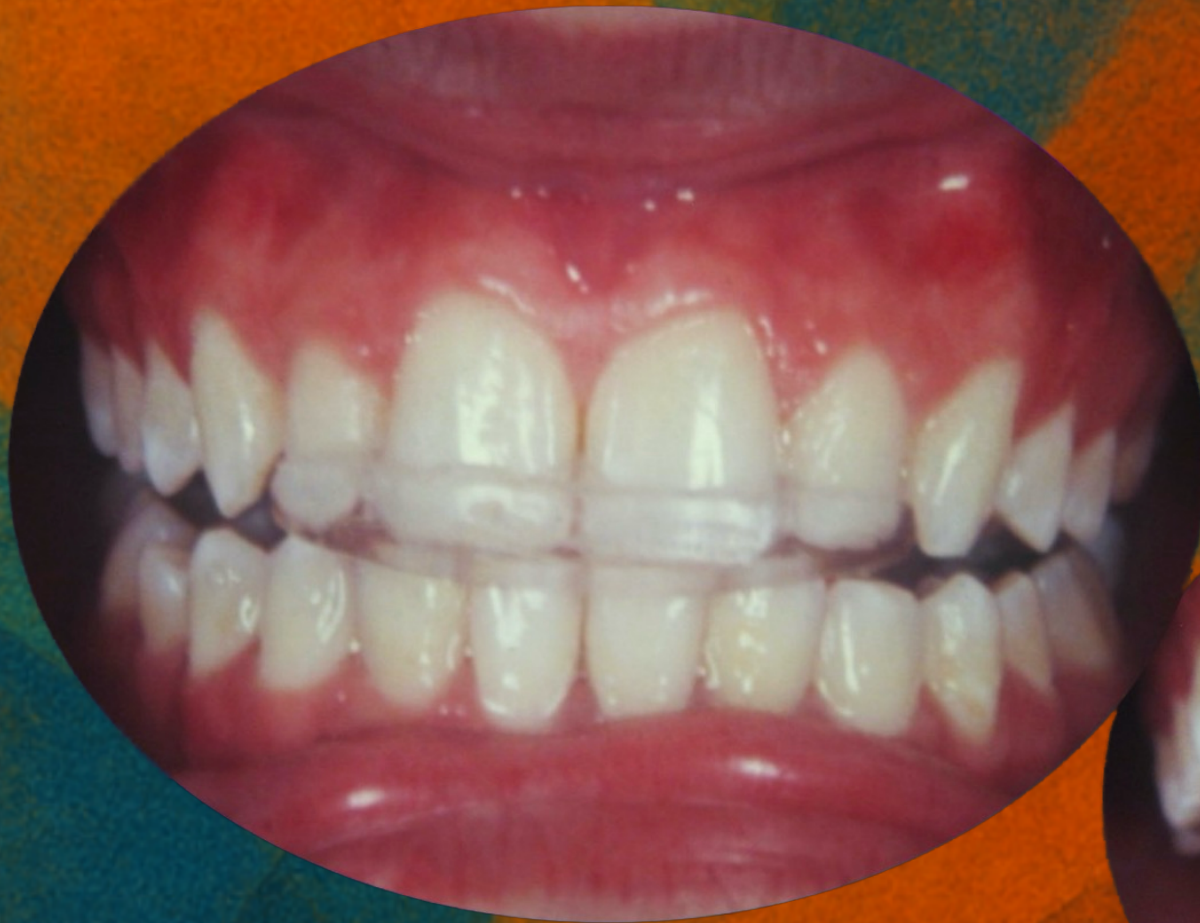


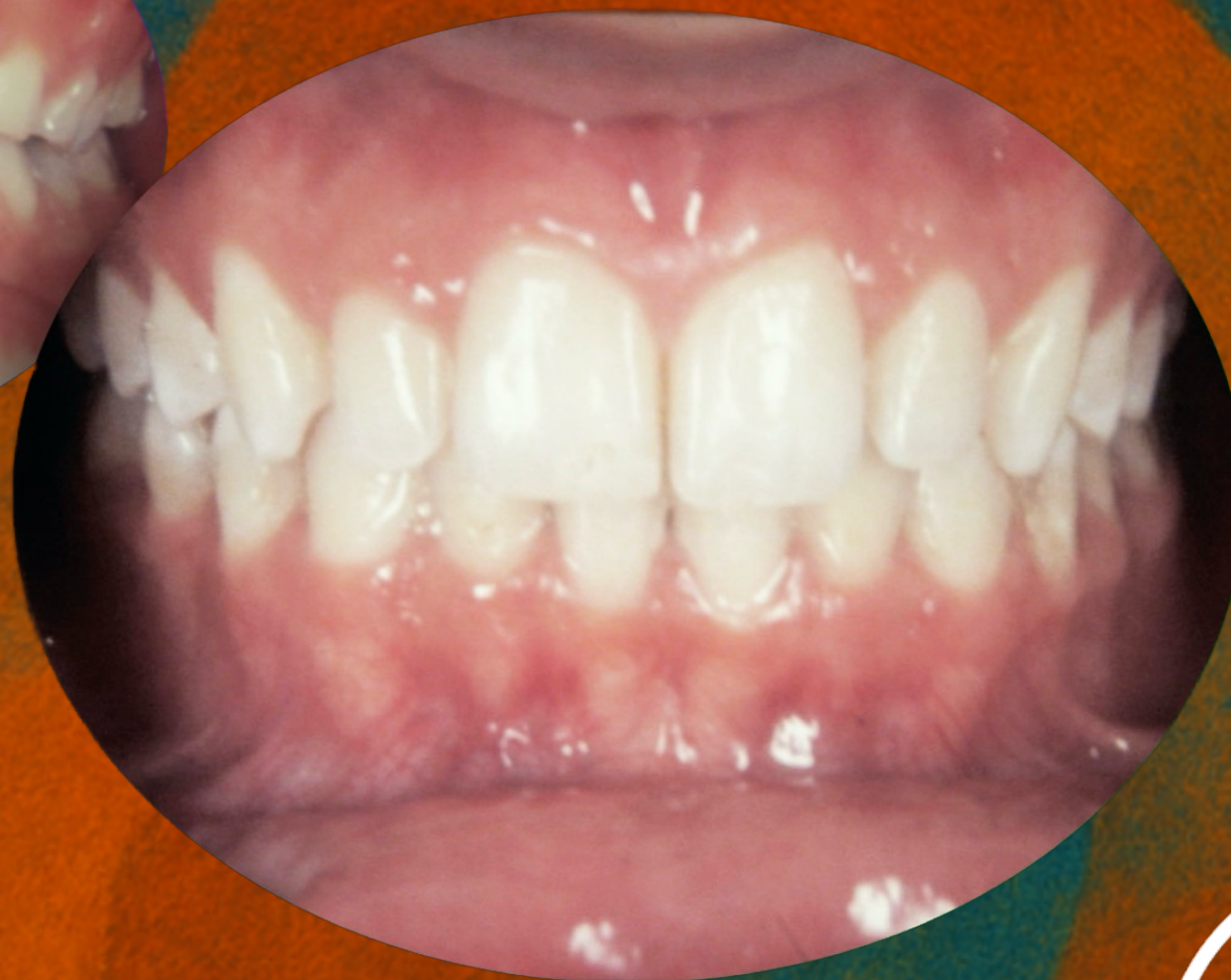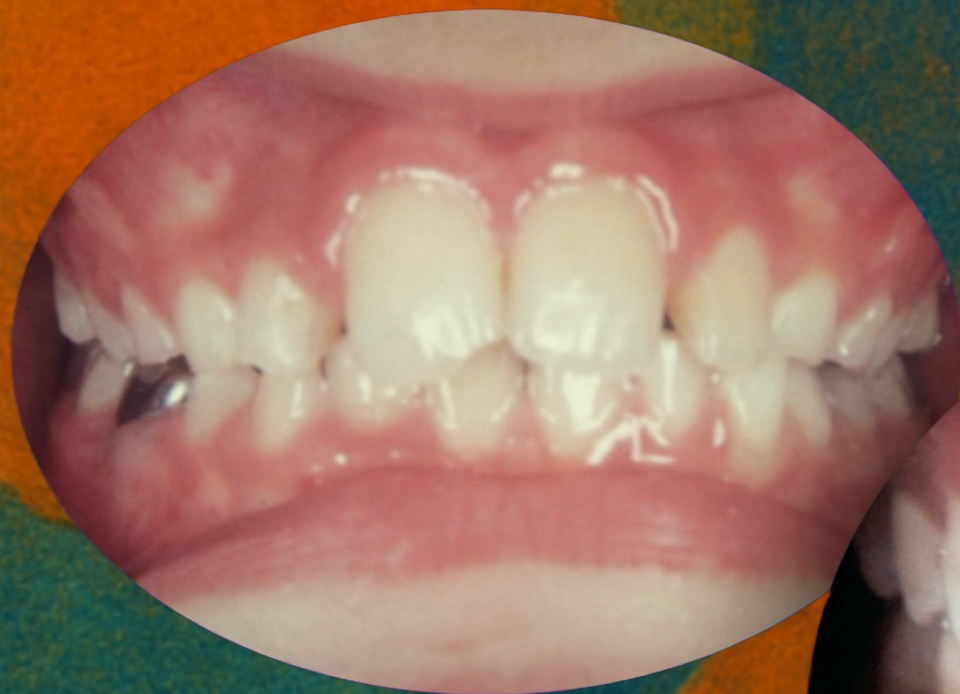Before and After



RDFM Monoblock appliance for occlusal stabilization





Before and After



www.odontologiasistemica.com

Systemic Odontology

